Pediatric Radiology
https://doi.org/10.1007/s00247-026-06594-2

REVIEW

Fetal and neonatal postmortem magnetic resonance imaging: indications protocols

Aurélie D'Hondt[1,2] · **Roxana Popa-Stanila**[3] · **Willemijn Klein**[4] · **Owen Arthurs**[5,6]

Received: 30 October 2025 / Revised: 26 February 2026 / Accepted: 14 March 2026
© The Author(s), under exclusive licence to Springer-Verlag GmbH Germany, part of Springer Nature 2026

Abstract

Postmortem magnetic resonance imaging (PMMRI) after fetal or perinatal death is now being adopted more widely in clinical settings as a non-invasive alternative or complementary approach to conventional autopsy. However, indications and imaging protocols vary significantly between centers and require standardization. Emerging advanced imaging techniques such as ultra-high-field MRI are very promising in smaller fetuses. In this article, we outline the current indications for PMMRI across different clinical scenarios and review consensus PMMRI protocols, together with a preview of future imaging possibilities enabled by 7-T MRI technology. We hope these recommendations will facilitate the standardization and implementation of perinatal PMMRI in clinical practice.

Graphical Abstract

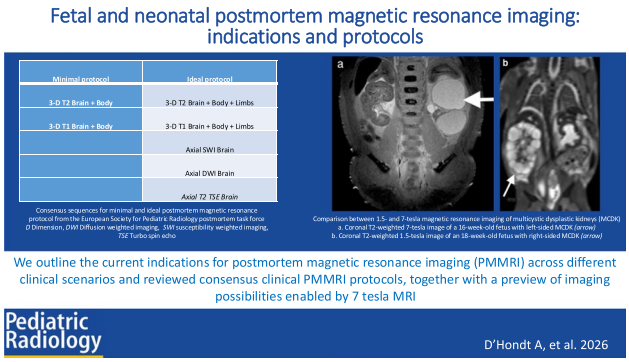

Keywords Imaging protocols · Magnetic resonance imaging · Perinatal mortality · Postmortem imaging

✉ Aurélie D'Hondt
aurelie.dhondt@outlook.com

Roxana Popa-Stanila
roxanatania@yahoo.com

Willemijn Klein
willemijn.klein@radboudumc.nl

Owen Arthurs
owen.arthurs@gosh.nhs.uk

[1] Department of Diagnostic and Interventional Radiology, Hospital for Sick Children, 555 University Avenue, Toronto, ON M5G1X8, Canada

[2] Université Libre de Bruxelles, Brussels, Belgium

[3] Iuliu Haţieganu University of Medicine and Pharmacy, Cluj-Napoca, Romania

[4] Radboud University Nijmegen Medical Centre, Nijmegen, Netherlands

[5] Great Ormond Street Hospital, London, United Kingdom

[6] Great Ormond Street Hospital Biomedical Research Centre, London, United Kingdom

Published online: 25 March 2026

Introduction

Postmortem magnetic resonance imaging (PMMRI) has become an increasingly important tool in fetal and neonatal care, serving both in the investigation of unexplained perinatal deaths and in the detailed evaluation of congenital anomalies [1].

The indication for PMMRI in the perinatal setting is broad and includes understanding the cause of unexpected intrauterine demise or perinatal death or confirmation of or any additive anomalies in termination of pregnancy. These indications may vary between countries due to differences in prenatal diagnostic work-up and termination legislation, and between centers, depending on clinical needs and available resources, such as the presence or absence of pediatric radiologists and fetal pathologists. The added value of PMMRI compared to prenatal testing, including genetics and ultrasonography, is not always clear.

Since its introduction, several pediatric PMMRI protocols have been proposed and published [2]. The earliest versions were intentionally extensive and highly detailed, typically developed within research environments, where scanning durations of up to 90 min were feasible [3]. However, such comprehensive methodologies have since proven difficult to translate into everyday clinical practice, largely due to limitations in scanner access and the practical time constraints inherent in routine imaging workflows [4]. In 2025, the European Society of Paediatric Radiology (ESPR) addressed this gap by endorsing expert consensus clinical PMMRI protocols executable within 30 min [5]. The ultimate goal was to help standardize practice by providing protocols that balance efficiency with accuracy for clinical implementation. Those protocols were developed to image fetuses and neonates on 1.5-T and 3-T scanners.

Ultra-high-field postmortem magnetic resonance imaging is emerging as a valuable tool for the non-invasive evaluation of fetal anatomy and pathology [6, 7]. It offers high spatial resolution, enabling detailed assessment of early gestational structures [8]. The groundwork for fetal PMMRI at ultra-high field (7 T) and higher (9–12 T) is still underway, with studies focused on the appearance of normal postmortem fetal structures (i.e., brain, heart, joints) [9–11] and others showing enhanced diagnostic accuracy in complex malformations [12–14]. Staicu A. et al. have demonstrated that whole-body 7-T PMMRI is feasible particularly at early gestation (13–19 weeks; n=30) when parental consent for invasive procedures is not given [15]. Despite certain technical and interpretative limitations, 7-T PMMRI represents a promising modality in perinatal pathology, bridging radiologic and histopathologic to improve postmortem diagnostic yield of small gestational ages fetuses. Small-bore MRI scanners, originally developed for preclinical research in small animals, enables virtopsy of first-trimester fetuses, extending imaging capabilities into the embryonic period, as early as 9 weeks of gestation [15]. However, ultra-high-field MRI is not the only modality suitable for imaging at early gestational ages. Micro-computed tomography (CT) offers even higher resolution than 9.4-T MRI for small fetuses (<20 weeks), particularly for skeletal and microanatomical structures. When combined with appropriate soft-tissue staining protocols, micro-CT can also provide excellent soft-tissue contrast. Optimal visualization of fetal anatomy may be achieved by combining micro-CT and ultra-high-field MRI, leveraging the complementary strengths of both modalities [16, 17].

In this article, we outline the current indications for PMMRI across different clinical scenarios and present the most recent consensus on PMMRI protocol endorsed by the ESPR. Furthermore, we provide an overview of future imaging possibilities enabled by 7-T MRI technology. While perinatal postmortem imaging remains a specialized field, it has growing importance in providing crucial information to families following fetal loss.

Indications for postmortem magnetic resonance imaging

Although PMMRI could be offered in all cases of fetal and perinatal death, the limited resource availability requires identifying clinical indications that are most likely to provide diagnostic value. PMMRI could be utilized together with genetic testing in all unexpected fetal deaths, although the diagnostic yield would be low and may not be cost-effective. Nevertheless, when performed alongside placental examination and external inspection of the body, the combined diagnostic yield of these non-invasive tests approaches that of a full invasive autopsy [18].

Ultimate cost-effectiveness may be better considered according to different categories of fetal demise, where PMMRI may be used, either to clarify prenatally diagnosed congenital abnormalities or to exclude abnormalities, and thus potentially avoid invasive autopsy.

1. In-utero demise. In unexpected fetal death prior to antenatal scanning, or following a normal prenatal ultrasound and/or fetal MRI, PMMRI can be useful to identify congenital abnormalities. As the fetus is anatomically normal in the majority of miscarriages at 16 weeks or above, PMMRI can be used to exclude abnormality and avoid invasive autopsy. The combination of routine external examination, placental examination, and postmortem imaging is likely to provide the highest yield rather than

invasive autopsy, particularly where PMMRI can provide diagnostic imaging of macerated fetuses which can be challenging to evaluate at autopsy.

2. Termination of pregnancy. In this context, PMMRI is used either to confirm the abnormality, search for other associated abnormalities as part of a spectrum, or exclude other known associations. Where PMMRI is concordant or in agreement with antenatal imaging findings, autopsy can be avoided [19, 20], particularly to meet parental preference.
3. Stillbirth. As the yield of conventional autopsy is low in stillbirth [21], PMMRI may negate the need for autopsy when normal. Indeed, the probability of identifying a histological or microscopic abnormality in an organ that is macroscopically normal or normal on imaging is very low, less than 1% [22].
4. Neonatal death. Due to the small number of studies and cases, the place of PMMRI in babies who have been born and subsequently die, irrespective of gestation, remains unclear. Interpreting findings such as hypoxic-ischemic encephalopathy in these settings may be challenging, as this may have occurred antemortem, intrapartum, or as part of the post-mortem process [23].

In many centers, postnatal confirmation of antenatal findings is required, either through autopsy or post-mortem imaging, depending on the availability of fetal or pediatric pathology services. When death is expected and the cause, such as structural anomalies, genetic diagnoses, or maternal disease, has been clearly established antenatally, PMMRI may provide limited additional diagnostic information. However, PMMRI remains valuable for confirming the abnormalities, or the normal findings, identified on prenatal ultrasound. Such confirmation can offer significant reassurance to parents and clinicians that no misdiagnosis occurred and that decisions regarding pregnancy termination were appropriate. It also supports more informed counselling for future pregnancies.

Postmortem magnetic resonance imaging protocols

Standard postmortem magnetic resonance imaging clinical protocols

Last year, the Postmortem Imaging Task Force of the ESPR has developed two standardized PMMRI protocols through expert consensus. Earlier versions, although comprehensive, were too lengthy for routine clinical application [24]. The finalized protocols now comprise a streamlined "minimal" protocol, containing only the essential sequences required for each body part, and an "ideal" or "best-practice" protocol designed for use when extended scanner time is available [5].

A modified Delphi process was undertaken among postmortem imaging experts from the ESPR, the Society for Pediatric Radiology, and the Australian and New Zealand Society for Paediatric Radiology. Using two previously published PMMRI frameworks [3, 24], this process resulted in a practical, consensus-based point-of-care protocol (Table 1).

The expert panel agreed that the *minimal* PMMRI protocol should include three-dimensional (3-D) isovolumetric T1- and T2-weighted imaging of the brain, spine, and thoraco-abdominopelvic regions. As the spinal column can be reconstructed from the torso dataset, a single whole-body acquisition encompassing both T1- and T2-weighted 3-D sequences was deemed sufficient for this version.

For the *ideal* PMMRI protocol, consensus supported the inclusion of comprehensive whole-body 3-D isovolumetric T1- and T2-weighted sequences covering the brain, spine, chest, abdomen, pelvis, and limbs as well as axial susceptibility-weighted imaging (SWI) and diffusion-weighted imaging (DWI) of the brain. When scanner time permits, an axial T2 turbo spin-echo (TSE) sequence of the brain may be added.

The ideal protocol introduces two principal enhancements relative to the minimal version: first, extension of 3-D whole-body imaging to include the limbs (particularly the lower limbs, as upper limbs are usually captured within standard torso coverage), and second, incorporation of advanced brain imaging sequences. For neuroimaging, experts advised supplementing the minimal protocol with axial SWI for improved detection of subtle hemorrhage and calcification, DWI/apparent diffusion coefficient (ADC) mapping, and, where feasible, additional axial T2-weighted imaging.

The choice between combined or separate acquisitions of brain and body should be guided by patient size.

In conclusion, a clinical perinatal PMMRI protocol should include at minimum 3-D isovolumetric T1- and T2-weighted sequences of the brain and body, acquired together. This two-sequence overview provides comprehensive anatomical coverage while maintaining efficiency,

Table 1 Consensus sequences for minimal and ideal postmortem magnetic resonance protocol from the European Society of Paediatric Radiology postmortem task force [5]

Minimal protocol	Ideal protocol
3-D T2 brain+body	3-D T2 brain+body+limbs
3-D T1 brain+body	3-D T1 brain+body+limbs
	Axial SWI brain
	Axial DWI brain
	Axial T2 TSE brain

DWI diffusion-weighted imaging, *SWI* susceptibility-weighted imaging, *TSE* turbo spin echo

with an average total scan time of less than 30 min. As the recommendations are independent of vendor type and magnetic field strength, this consensus framework supports international standardization of PMMRI acquisition and facilitates broader clinical adoption of perinatal postmortem MRI.

Advanced postmortem magnetic resonance imaging protocols

For early gestational-age fetuses, 1.5-T or 3-T scanners typically provide insufficient signal-to-noise ratio for adequate image analysis. However, image quality can be improved by placing the fetus in a saline-filled syringe or positioning a saline bag adjacent to the body [25]. In all cases, using the smallest available coil helps optimize signal reception. Higher field strength scanners may give additional yield, particularly at early gestational-age fetuses [26]. However, its clinical application remains limited due to the scarcity of 7-T and 9.4-T MRI systems, with less than 100 units in clinical use worldwide [27]. Most studies have utilized small-bore preclinical systems, equipped with high-performance gradient coils offering image quality at a cost comparable to standard clinical MRI. Ultra-high-field PMMRI at 9.4 T has proven particularly effective for imaging small fetuses, offering whole-body evaluation or targeted imaging of organs such as the heart, especially when conventional autopsy is limited or not feasible [28, 29].

How to perform a high-field strength PMMRI

Several key factors must be considered when performing fetal PMMRI at ultra-high-field strength, including specimen size, formalin fixation, specimen temperature, duration of intrauterine retention post-demise, and protocols, an example of which is given in Table 2 for 7-T PMMRI [15, 30]. Standardizing protocols across institutions remains challenging, as data from small-bore research systems may not directly translate to clinical, large-bore scanners. Differences in gradient performance, spatial resolution, and radiofrequency coil design between preclinical and clinical systems must be accounted for. Nevertheless, developments in human 7-T systems, such as next-generation gradient coils achieving ~200 mT/m and 900 T/m/s slew rates (e.g., head-only designs), are narrowing the gap between preclinical and clinical performance, while remaining within safety and physiological constraints [32]. For comparison, Table 3 presents two sample imaging protocols for 9.4-T fetal PMMRI.

Feasibility and cost considerations

In high-volume referral centers, investing in a dedicated small-bore 7-T MRI system may be justified. The hardware and basic installation costs range from approximately $1.0–2.5 million for refurbished systems, and $2.5–4 million USD for new units, depending on configuration, optional add-ons, and regional variations [33]. Operational costs, including technical and radiologic expertise, vary regionally.

Table 2 Practical considerations and example protocol for 7-T fetal postmortem magnetic resonance imaging [15]

Parameter	Details/recommendations
Fetal size	Embryos: 9–10 weeks gestation (CRL 4–8 cm, weight 1–2 g): most anatomical structures visible Fetuses: 13–19 weeks gestation with a maximal weight of 364 g (to fit the bore)
Formaldehyde fixation	Needed to preventing tissue degradation 10% formaldehyde at room temperature (20–23 °C) Duration inversely proportional to gestational age: 6–8 weeks for embryos, 48 h–1 week for fetuses Embryos scanned immersed or out of solution (contrast improves after removal) Fetuses scanned in plastic bag without solution to protect scanner
Sample temperature	Influences T2-weighted sequence quality (indifferent of field strength [31]) Water-rich tissues (brain) → better contrast at low temperature Soft tissues → higher temperature needed Embryos and fetuses stored at 4 °C prior to PMMRI Scan order: the nervous system first, then thorax/abdomen
Timing/intrauterine retention	Shorter interval between fetal demise and PMMRI results in better image quality
Protocols	Embryos: 3-D fast imaging with steady procession sequence Fetuses: Turbo spin-echo high-resolution T2-weighted sequences in axial, sagittal, coronal, and sagittal planes of the head and body For both: 2-D tri-pilot for geometry analysis in 3 planes
Acquisition parameters	0.0102–0.0104 cm/pixel resolution, 2–5 cm image size, 384×384 matrix, 62,500 Hz bandwidth, 5 repetitions at 20 °C, 0.5-mm slices with 0.75-mm interslice distance Repetition time: 3,442–62,909 ms; echo time: 36 ms
Scanning time	Average embryo scan time 21.6 h (17–24 h) Average fetal scan time 61 min (49.28–315.28 min)

CRL crown-rump length, *PMMRI* postmortem magnetic resonance imaging, *D* dimensional

Table 3 Examples of published 9.4-T fetal postmortem magnetic resonance protocols

Study	Sequence	TR (ms)	TE (ms)	Voxel size (mm^3)	Matrix size	FOV (mm)	Scan time	Target area
Tang et al. (2022) [28]	T1-weighted	6	2.9	0.32×0.32×0.4	256×256×80–120	32×32	Not specified	Fetal heart and thoracic structures
Thayyil et al. (2009) [29]	T2-weighted	500	120	0.1×0.05×0.05	512×256×256	100×50×50	70 min	Whole-body fetal anatomy

FOV field of view, *TE* echo time, *TR* repetition time

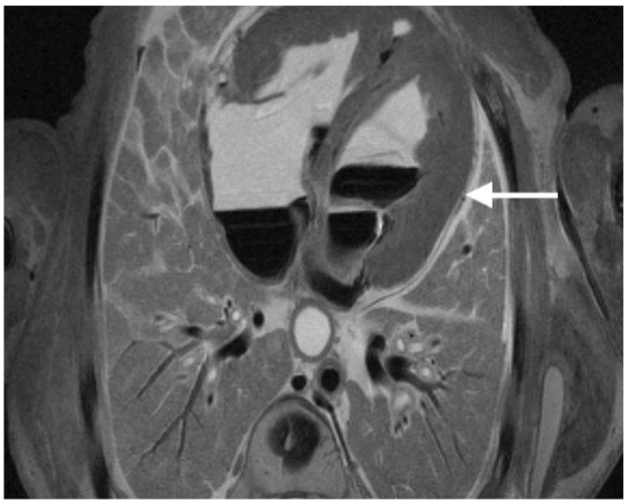

Fig. 1 7-T postmortem magnetic resonance imaging turbo spin-echo high-resolution axial T2-weighted images of an 18-week-old male fetus, after termination of pregnancy, with left ventricular hypertrophy (*arrow*) secondary to aortic coarctation, confirmed at autopsy

Added value of ultra-high-field fetal postmortem magnetic resonance imaging

The added value of ultra-high-field fetal PMMRI has been highlighted in initial studies demonstrating notable diagnostic advantages in fetal pathologies (Figs. 1, 2, and 3) particularly in early gestational fetuses, with increased spatial resolution compared to conventional MRI scanners (Figs. 4 and 5). Reported performance metrics indicate high diagnostic accuracy approaching 95%, specificity up to 98%, and a negative predictive value of 96% compared to conventional autopsy [15, 29]. High-resolution imaging allows detailed visualization of internal organs (Fig. 6) and the fetal skeleton. This is particularly useful at early gestational ages, when conventional autopsy is technically limited, and in cases of advanced autolysis, where tissue degradation reduces diagnostic yield. Indeed PMMRI at 7 T was superior to conventional autopsy for analyzing the central nervous system in small fetuses with pronounced autolysis, equivalent for the lungs/heart/kidneys, inferior for the bowels [15].

These capabilities position ultra-high-field PMMRI as a valuable and reliable complement or, in some cases,

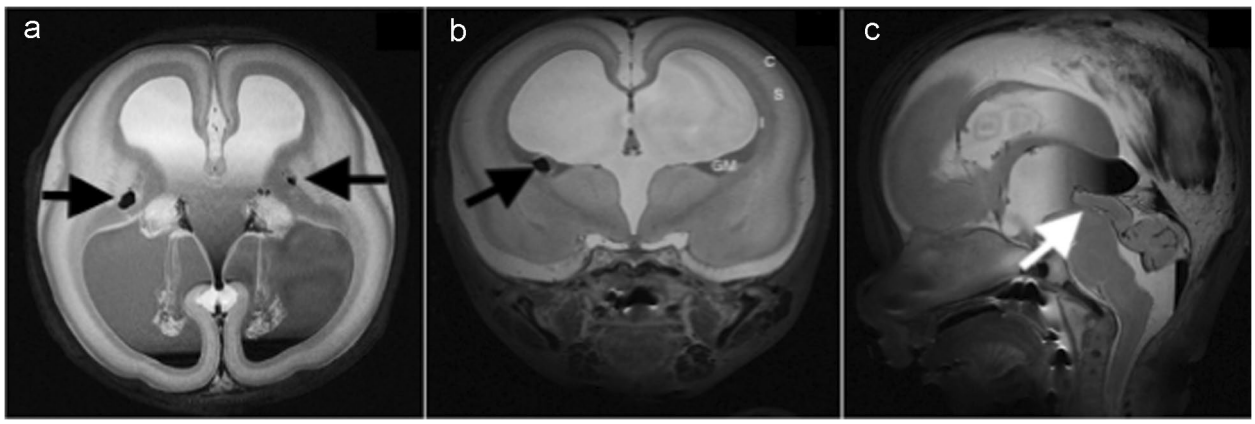

Fig. 2 7-T postmortem magnetic resonance imaging of a 17-week-old male fetus, after termination of pregnancy, with triventricular dilatation secondary to aqueduct stenosis. **a** Axial T2-weighted image shows dilatation of the lateral ventricles, germinal matrix hemorrhage (*arrows*), and intraventricular hemorrhage with fluid-fluid layering. **b** Coronal T2-weighted image shows dilation of the lateral and third ventricles, germinal matrix hemorrhage (*arrow*) and normal brain lamination. **c** Sagittal T2-weighted image shows the aqueductal stenosis (*arrow*), confirmed at autopsy. The corpus callosum appears elongated due to the ventriculomegaly. *C* cortex, *GM* germinal matrix, *I* intermediate zone, *S* subplate layer

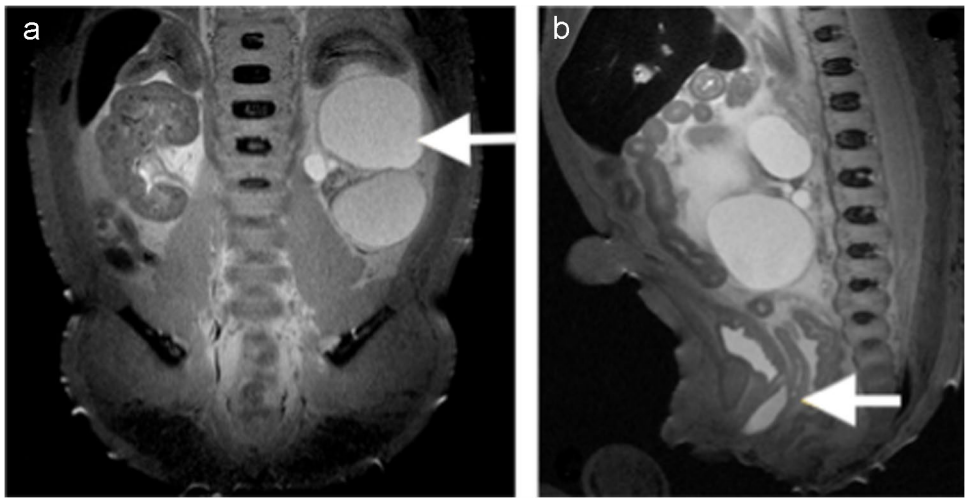

Fig. 3 7-T postmortem magnetic resonance imaging coronal (**a**) and sagittal (**b**) T2-weighted images in a 16-week-old female fetus, after termination pregnancy, with multicystic dysplastic left kidney (**a**, *arrow*) and ectopic insertion of left ureter (**b**, *arrow*)



Fig. 4 1.5-T postmortem magnetic resonance imaging axial 2-dimensional T2-weighted image of a 20-week-old male fetus, after intrauterine demise, with small bilateral ventricular hemorrhage (*arrows*) and normal brain

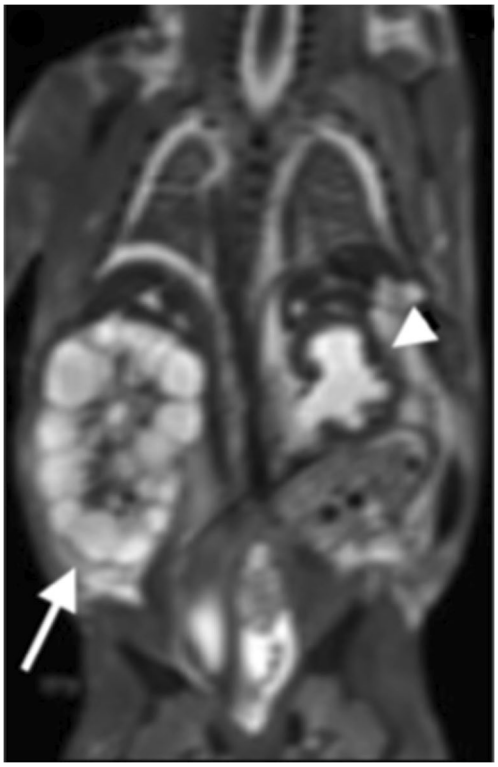

Fig. 5 1.5-T postmortem magnetic resonance imaging coronal 2-dimensional T2-weighted image of an 18-week-old female fetus, after termination of pregnancy, with right-sided multicystic dysplastic kidney (*arrow)* and left-sided hydronephrosis (*arrowhead*)

an alternative to traditional autopsy in perinatal pathology. Ultra-high-field PMMRI also has broader clinical and academic implications. As a non-invasive alternative to autopsy, it may increase parental acceptance, particularly among families who decline invasive procedures for cultural or religious reasons. Moreover, it provides an invaluable educational resource for training radiologists, pathologists, and medical students. Its reproducibility and high

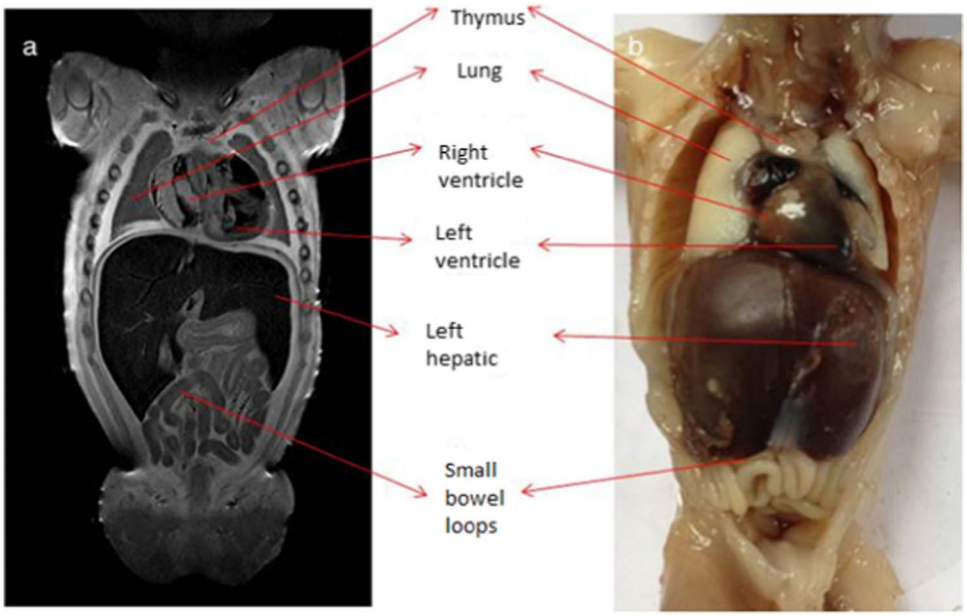

Fig. 6 7-T postmortem magnetic resonance imaging coronal 2-dimensional T2-weighted images (**a**) and macroscopic comparison (**b**) in a 12-week-old normal fetus after termination of pregnancy

anatomical fidelity make it an ideal tool for research into fetal development and congenital anomalies.

Limitations of ultra-high-field fetal postmortem magnetic resonance imaging

Despite its advantages, ultra-high-field PMMRI has several limitations. The technique has reduced sensitivity for detecting certain gastrointestinal anomalies and remains unable to identify microscopic pathological changes, such as those revealed through histological assessment or in the diagnosis of infections [15, 29]. Practical challenges include limited accessibility of ultra-high-field MRI scanners and the requirement for fetal fixation in formaldehyde. These limitations underscore the importance of integrating PMMRI with complementary imaging modalities (e.g., micro-CT [34]) and conventional pathology to ensure a comprehensive postmortem evaluation. In a direct head-to head comparison of imaging techniques in eight fetuses, the highest diagnostic yield was obtained from micro-CT, then 9.4-T PMMRI, then ultrasound [16] which may help plan optimal clinical imaging strategies for small fetuses in the future.

Future directions

Further research is needed to validate current findings across larger, multicenter studies and different populations. The indications for PMMRI and its added value—particularly in neonates—require further clarification. Future developments may include optimized imaging sequences for faster acquisition, automated image analysis, advancements in ultra-high-field MRI (e.g., 9.4 T and beyond) for superior anatomical resolution and multimodal imaging approaches, and/or combining PMMRI with micro-CT and other modalities for comprehensive assessment. Moreover, international working groups with access to 7-T scanners are needed to enable robust multicenter studies. Readers are welcome to contact the authors for support or guidance in developing a 7-T postmortem imaging service.

In conclusion, there is a need to further delineate fetal and neonatal postmortem indications. Standardized PMMRI protocols should ease the implementation of PMMRI in clinical practice. The future of postmortem imaging is very promising for imaging small gestational age fetuses with ultra-high-field strength MRI.

Acknowledgements Aurélie D'Hondt acknowledges the support of the "Belgian Kids Fund" through a personal PhD grant.

Author contribution All authors contributed to the manuscript conception. The first draft of the manuscript was written by A.D., R.P., and W.K.. O.A. commented on all versions of the manuscript. All authors read and approved the final manuscript.

Data availability No datasets were generated or analysed during the current study.

Declarations

Competing interests The authors declare no competing interests.

References

1. Shelmerdine SC, Arthurs OJ (2023) Post-mortem perinatal imaging: what is the evidence? Br J Radiol 96:20211078
2. Shelmerdine SC, Hutchinson JC, Lewis C, Simcock IC, Sekar T, Sebire NJ, Arthurs OJ (2021) A pragmatic evidence-based

approach to post-mortem perinatal imaging. Insights Imaging 12:101. https://doi.org/10.1186/s13244-021-01042-1
3. Norman W, Jawad N, Jones R, Taylor AM, Arthurs OJ (2016) Perinatal and paediatric post-mortem magnetic resonance imaging (PMMR): sequences and technique. Br J Radiol 89:1062. https://doi.org/10.1259/bjr.20151028
4. Chambers G, Shelmerdine SC, Aertsen M, Dohna M, Goergen SK, Johnson K, Klein WM, Miller E, Pärtan G, Perry D, Rao P, Robinson C, Stegmann J, Taranath A, Whitby E, van Rijn RR, Arthurs OJ (2023) Current and future funding streams for paediatric postmortem imaging: European Society of Paediatric Radiology survey results. Pediatr Radiol 53:273–281. https://doi.org/10.1007/s00247-022-05485-6
5. D'Hondt A, Shelmerdine S, Aertsen M, Cassart M, Miller E, Klein W, Goergen S, Victoria T, Blondiaux E, Alison M, Abel C, Taranath A, Rebollo Polo M, Meyers ML, Gomez-Chiari M, Rao P, van Rijn RR, Arthurs O (2025) Fetal and neonatal postmortem magnetic resonance imaging clinical protocol: recommendations from the European Society of Paediatric Radiology Postmortem Task Force. Pediatr Radiol. Published online. https://doi.org/10.1007/s00247-025-063
6. Lamouroux A, Cardoso M, Bottero C, Gallo M, Duraes M, Salerno J, Bertrand M, Rigau V, Fuchs F, Mousty E, Genevieve D, Subsol G, Goze-Bac C, Captier G (2024) Micro-CT and high-field MRI for studying very early post-mortem human fetal anatomy at 8 weeks of gestation. Prenat Diagn 44:3–14
7. Blondiaux E, Autret G, Dhombres F, Gonzales M, Audureau E, Clément O, Jouannic JM, Houyel L (2019) Evaluation of septal insertion of atrioventricular valves in fetuses by postmortem 4.7 tesla cardiac MRI: a feasibility study. Diagn Interv Imaging 100:109–116
8. Lin X, Zhang Z, Teng G, Meng H, Yu T, Hou Z, Fang F, Zang F, Liu S (2011) Measurements using 7.0 T post-mortem magnetic resonance imaging of the scalar dimensions of the fetal brain between 12 and 20 weeks gestational age. Int J Dev Neurosci 29:885–889
9. Albu C, Staicu A, Popa-Stanilă R, Bondor C, Pop B, Chiriac L, Gheban D, Micu R, Turcu RVF, Simon S, Crișan D, Stamatian F (2022) The evaluation of the four-chamber cardiac dissection method of the fetal heart as an alternative to conventional inflow-outflow dissection in small gestational-age fetuses. Diagnostics (Basel) 12:223
10. Josemans SH, van der Post AS, Strijkers GJ, Dawood Y, van den Hoff MJB, Jens SRJ, Obdeijn MC, Oostra RJ, Maas M (2023) Ultra-high-field MRI of postmortem human fetal wrist joints: initial experience. Eur Radiol Exp 5:28. https://doi.org/10.1186/s41747-023-00341-0
11. Boitor-Borza D, Turcu F, Farcasanu S, Crivii C (2021) Early development of human ganglionic eminences assessed in vitro by using 7.04 Tesla micro-MRI - a pilot study. Med Pharm Rep 94:35–42. https://doi.org/10.15386/mpr-1715
12. Albu C, Staicu A, Popa-Stănilă RT, Milaş AC, Chiriac LB, Kovács TE, Stamatian VF (2018) Multidisciplinary approach of assessing malformed fetuses exemplified in a rare case of pentalogy of Cantrell associated with craniorachischisis, pulmonary extrophy and right-sided aortic arch with aberrant brachiocephalic artery. Rom J Morphol Embryol 59:911–915
13. Du M, Wang D, Zhang Y, Jiang L, Cai P, Chen W (2024) Postmortem 7T MRI in Goltz-Gorlin syndrome: insights into fetal anomalies beyond conventional imaging techniques. Eur J Radiol 174:111390
14. Staicu A, Popa-Stanilă R, Gheban D, Chiriac L, Turcu FR, Caracostea G, Stamatian F (2016) Imagistic and histopathological description of a cystic nephroma during early second trimester of gestation. Case report. Med Ultrason 19:327–329
15. Staicu A, Albu C, Popa-Stanila R, Bondor C, Chiriac L, Eniu D, Goidescu I, Florian AR, Surcel M, Cruciat G, Muresan D, Rotar I (2024) Whole-body non-forensic fetal virtopsy using postmortem magnetic resonance imaging at 7 tesla vs classical autopsy. Ultrasound Obstet Gynecol 64:661–668
16. Ibarra Vilar P, Jani JC, Cannie MM, Shelmerdine SC, Lecomte S, Verhoye M, Hutchinson CJ, Arthurs OJ, Carlin A, Kang X (2024) Postmortem imaging of fetuses at early gestations: a comparison of microfocus computed tomography with postmortem magnetic resonance at 9.4 T and postmortem ultrasound. Prenat Diagn 44:572–579
17. Dawood Y, Honhoff C, van der Post AS, Roosendaal SD, Coolen BF, Strijkers GJ, Pajkrt E, de Bakker BS (2022) Comparison of postmortem whole-body contrast-enhanced microfocus computed tomography and high-field magnetic resonance imaging of human fetuses. Ultrasound Obstet Gynecol 60:109–117. https://doi.org/10.1002/uog.24827
18. Simcock IC, Lamouroux A, Shelmerdine SC, Sebire NJ, Hutchinson JC, Arthurs OJ (2025) Clinical experience of a fetal postmortem imaging service using microfocus computed tomography. Am J Obstet Gynecol 9378:00413-2. https://doi.org/10.1016/j.ajog.2025.06.035.
19. Shelmerdine SC, Arthurs OJ, Gilpin I, Norman W, Jones R, Taylor AM, Sebire NJ, Chitty LS (2019) Is traditional perinatal autopsy needed after detailed fetal ultrasound and post-mortem MRI? Prenat Diagn 39:818–829
20. Moeremans M, Avni FE, d'Haene N, Lam NM, Metens T, D'Hondt A (2024) Combined prenatal US and post-mortem fetal MRI: can they replace conventional autopsy for fetal body abnormalities? Eur Radiol 34:632–642
21. Man J, Hutchinson JC, Heazell AE, Ashworth M, Jeffrey I, Sebire NJ (2016) Stillbirth and intrauterine fetal death: role of routine histopathological placental findings to determine cause of death. Ultrasound Obstet Gynecol 48:579–584
22. Man J, Hutchinson JC, Ashworth M, Judge-Kronis L, Levine S, Sebire NJ (2016) Stillbirth and intrauterine fetal death: role of routine histological organ sampling to determine cause of death. Ultrasound Obstet Gynecol 48:596–601
23. Arthurs OJ, Barber JL, Taylor AM, Sebire NJ (2015) Normal perinatal and paediatric postmortem magnetic resonance imaging appearances. Pediatr Radiol 45:527–535
24. Whitby E, Offiah AC, Shelmerdine SC, van Rijn RR, Aertsen M, Klein WM, Perry D, Goergen SK, Abel C, Taranath A, Gascho D, Miller E, Arthurs OJ (2021) Current state of perinatal postmortem magnetic resonance imaging: European Society of Paediatric Radiology questionnaire-based survey and recommendations. Pediatr Radiol 51:792–799. https://doi.org/10.1007/s00247-020-04905-9
25. Kang X, Cannie M, Jani J (2025) Post mortem MRI. In: Arthurs OJ (ed) Post mortem imaging of the fetus & child. Springer, pp 111–138
26. Dawood Y, Strijkers GJ, Limpens J, Oostra RJ, de Bakker BS (2020) Novel imaging techniques to study postmortem human fetal anatomy: a systematic review on microfocus-CT and ultra-high-field MRI. Eur Radiol 30:2280–2292. https://doi.org/10.1007/s00330-019-06543-8
27. Cosottini M, Roccatagliata L (2021) Neuroimaging at 7 T: are we ready for clinical transition? Eur Radiol Exp 5:37
28. Tang H, Zhang Y, Dai C, Ru T, Li J, Chen J, Zhang B, Zhou K, Lv P, Liu R, Zhou Q, Zheng M (2022) Postmortem 9.4-T MRI for fetuses with congenital heart defects diagnosed in the first trimester. Front Cardiovasc Med 8:764587
29. Thayyil S, Cleary JO, Sebire NJ, Scott RJ, Chong K, Gunny R, Owens CM, Olsen OE, Offiah AC, Parks HG, Chitty LS, Price AN, Yousry TA, Robertson NJ, Lythgoe MF, Taylor AM (2009) Post-mortem examination of human fetuses: a comparison of

whole-body high-field MRI at 9.4 T with conventional MRI and invasive autopsy. Lancet 37:467–475
30. Staicu A, Albu C, Popa-Stanila R, Chiriac L, Boitor-Borza D, Bondor C, Kovacs T, Caracostea G, Rotar IC, Turcu RVF, Simon S, Muresan D, Stamatian F (2019) Potential clinical benefits and limitations of fetal virtopsy using high-field MRI at 7 tesla versus stereomicroscopic autopsy to assess first trimester fetuses. Prenat Diagn 39:505–518
31. Berger C, Bauer M, Wittig H, Scheurer E, Lenz C (2022) Post mortem brain temperature and its influence on quantitative MRI of the brain. MAGMA 3:375–387
32. Feinberg DA, Beckett AJS, Vu AT, Stockmann J, Huber L, Ma S, Ahn S, Setsompop K, Cao X, Park S, Liu C, Wald LL, Polimeni JR, Mareyam A, Gruber B, Stirnberg R, Liao C, Yacoub E, Davids M, Bell P, Rummert E, Koehler M, Potthast A, Gonzalez-Insua I, Stocker S, Gunamony S, Dietz P (2023) Next-generation MRI scanner designed for ultra-high-resolution human brain imaging at 7 tesla. Nat Methods 20:2048–2057
33. https://www.bruker.com/en/products-and-solutions/preclinical-imaging/mri/biospec/biospec-70-30-and-94-30.html
34. Simcock IC, Shelmerdine SC, Hutchinson JC, Sebire NJ, Arthurs OJ (2021) Human fetal whole-body postmortem microfocus computed tomographic imaging. Nat Protoc. https://doi.org/10.1038/s41596-021-00512-6

Publisher's Note Springer Nature remains neutral with regard to jurisdictional claims in published maps and institutional affiliations.

Springer Nature or its licensor (e.g. a society or other partner) holds exclusive rights to this article under a publishing agreement with the author(s) or other rightsholder(s); author self-archiving of the accepted manuscript version of this article is solely governed by the terms of such publishing agreement and applicable law.