Pediatric Radiology
https://doi.org/10.1007/s00247-026-06634-x

RESEARCH

Standardised structured foetal and neonatal postmortem magnetic resonance imaging reporting: recommendations from the European Society of Paediatric Radiology Postmortem Task Force

Aurélie D'Hondt · Marie Cassart · Elka Miller · Willemijn M. Klein · Susan Shelmerdine · Michael Aertsen, et al. ***[full author details at the end of the article]***

Received: 10 March 2026 / Revised: 22 April 2026 / Accepted: 26 April 2026
© The Author(s), under exclusive licence to Springer-Verlag GmbH Germany, part of Springer Nature 2026

Abstract

Background The use of standardised structured radiology reports improves the consistency, reproducibility and overall quality of radiological reporting while enhancing communication with referring physicians and ultimately contributing to improved patient care.

Objective To develop a standardised structured report template for foetal and neonatal postmortem magnetic resonance imaging through expert consensus.

Materials and methods A Delphi survey was conducted between September and December 2025 among members of the ESPR Postmortem Task Force and other recommended international PM imaging experts. The surveyed items were derived from clinically used MRI reporting templates across the expert group. Consensus was defined using a ≥75% agreement threshold, and items meeting this criterion were incorporated into the final point-of-care template.

Results Twenty-four postmortem imaging specialists from 22 centres worldwide (Europe, USA, Canada, Australia, New Zealand, India and South America) formed our expert panel and completed the survey. By consensus, the final structured PMMRI report template includes the following subheadings: expected postmortem changes, cerebral structures, cervico-thoracic structures, abdominal structures and extremities, each accompanied by a defined list of anatomical structures to be assessed, followed by a conclusion. In addition, the indication and technique sections of the report were based on prior consensus recommendations from the ESPR PM Task Force.

Conclusion A standardised and structured reporting template for foetal and neonatal PMMRI was developed through expert consensus to promote complete, clear and consistent reporting and to facilitate communication. These recommendations aim to promote standardisation and wider adoption of perinatal PMMRI in clinical practice.

Graphical abstract

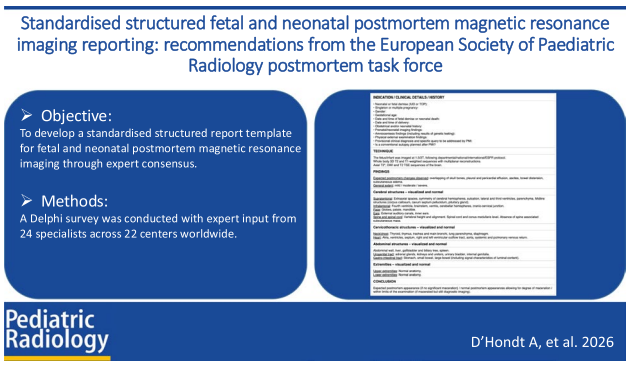

Keywords Consensus recommendations · Magnetic resonance imaging · Perinatal death · Postmortem imaging · Structured reporting

Published online: 12 May 2026

Introduction

Postmortem magnetic resonance imaging (PMMRI) is increasingly used in paediatric and foetal medicine, both for the assessment of unexpected deaths and for the evaluation of foetal malformations [1]. The written imaging report represents the primary means by which radiologists communicate examination findings to referring clinicians [2]. *Standardised reporting* refers to the harmonisation of the medical content of radiology reports, whereas *structured reporting* refers to the organisation of this content within a digitally integrated radiology report template [3].

Numerous radiological societies advocate the adoption of standardised and structured reporting practices to enhance the consistency, reproducibility and clarity of imaging terminology, as well as to improve adherence to international guidelines [4–9]. The use of uniform language and consistent report structure is essential to accurately describe imaging findings and to ensure that all relevant anatomical regions are systematically addressed. Standardisation also facilitates comparison between reports, supports multidisciplinary communication, and enables secondary use of data for research and quality improvement purposes [10].

In this context, the European Society for Paediatric Radiology (ESPR) foetal Task Force has recently developed a standardised and structured reporting template for antenatal foetal MRI [11]. There are many similarities between antenatal and postmortem foetal imaging, where whole-body assessment is performed and a large number of anatomical structures must be evaluated, with additional postmortem considerations. In this setting, standardised and structured reporting has substantial potential to improve the quality, completeness and clinical value of radiological reports for both referring physicians and families [12]. Furthermore, the growing integration of large language models into clinical workflows may further facilitate the implementation and adoption of structured reporting in radiology in the near future [13].

The aim of this study was to develop a standardised structured reporting template for foetal and neonatal PMMRI, defined by experts in postmortem imaging, to facilitate communication between radiologists and referrers and improve patient care.

Materials and methods

This was a prospective international, multicentre Delphi survey. Ethical approval was not required as no patient data were shared or accessed. No funding sources were sought for this project.

Selection of experts

Our panel of experts was recruited through email invitation to registered members of the European Society of Paediatric Radiology (ESPR) PM taskforce and other PM imaging specialists worldwide, including some of the Society of Paediatric Radiology (SPR) postmortem imaging committee, the Australian and New Zealand Society of Paediatric Radiology (ANZSPR), the Asian-Oceanic Society for Paediatric Radiology (AOSPR) and the Societad Latinoamericana de Radiología Paediátrica (SLARP). Recommendation of additional experts for this study by word of mouth by our panelists was also encouraged. Our experts were recruited given their clinical interest and experience in practicing postmortem imaging for foetal and neonatal cases.

Survey development

The lead author (A.D.; 5 years' experience of paediatric radiology), senior author (O.J.A.; 16 years' experience of paediatric radiology) and a selected group of panel members (E.M.; 20 years' experience of paediatric radiology, S.G.; 30 years' experience of paediatric radiology and M.C.; 30 years' experience of paediatric radiology) collated all items included in the postmortem imaging report template currently used across their 5 institutions and drafted an initial structured report template. The authors agreed that the report should follow a standardised structure, beginning with indication/history, followed by technique, findings (the body of the report) and conclusion. As the ESPR PM Task Force recently defined the clinical information required prior to performing a PMMRI (indication/history) [14] as well as recommendations for clinical PMMRI acquisition protocols (technique) [15], the present survey only addressed the findings and conclusion sections of the report.

The final survey was divided into several categories: expected postmortem changes, cerebral structures, cervicothoracic structures, abdominal structures, extremities and conclusion. For each subheading, a list of anatomical structures was compiled, and a Delphi online survey was created (Supplementary Material).

Experts were asked to select all items (anatomical structures) that they routinely assessed and indicate if they should be included in a structured foetal or neonatal PMMRI report template, thereby predefining a list of reportable items for a normal examination, including default statements (e.g. "normal anatomy"), while providing a structured framework for documenting and localising abnormalities when present. The definition of foetal or neonatal for the purpose of this project was the period spanning any foetal gestational age to postnatal day 28 following a live birth. Optional free-text fields were provided to allow experts to share additional comments or suggestions.

A threshold of 75% agreement among all respondents was defined as indicating consensus; items that did not reach this level were excluded from the final report template. This approach is consistent with commonly accepted Delphi methodology, in which consensus thresholds typically range from 70% to 80%. A 75% cutoff is frequently adopted as it reflects a high level of agreement while allowing for reasonable variability in expert opinion [16].

Data collection

An online Delphi survey was created in Google Forms (Google LLC, Mountain View, CA). An email containing the link to the survey was sent out in October 2025. A reminder was sent out in November 2025 and all responses were received by December 2025.

All panelist responses were anonymised in this study, known only to the lead author collecting the data, to avoid duplication of entries, to avoid any bias in opinions. The results of the survey were collected and analysed in a descriptive manner, and a point-of-care structured report template was drafted based on the agreed items of our expert panelists. The final version of this manuscript was circulated among authors in 2026 for consensus approval and formally endorsed by the ESPR board before submission for publication.

Results

Email invitations to participate in the Delphi survey were sent to 29 members of different international postmortem-imaging taskforces (ESPR, SPR, ANZSPR, AOSPR and SLARP). The survey was completed by 24 participants (83% response rate) from 22 different institutions across 13 different countries (seven in Europe Belgium, Spain, UK, France, the Netherlands, Italy, Ireland; and six non-European: (USA, Canada, Australia, New Zealand, India and Chile).

The main body of the report included 52 items. The results of the Delphi survey for each item are displayed in Table 1. Six of the 52 items (retrocerebellar cerebrospinal fluid (CSF) spaces, ocular spacing, pinnae, rectum (position relative to bladder neck), number of rays/digits for the upper and lower extremities) did not reach the predefined consensus threshold and were therefore excluded from the final report template.

The conclusion of the report included 2 items. The results of the modified Delphi study for each item are presented in Table 1. One item (No morphological abnormalities identified) did not reach the predefined consensus threshold and was therefore excluded from the final report template.

All items that achieved consensus among the expert panel were incorporated.

The overall level of agreement among experts across the 54 proposed items was 87%. Based on these results, we developed a point-of-care structured reporting template for foetal and neonatal PMMRI (Fig. 1), together with the previously defined indication and technique templates.

Discussion

A high level of agreement was achieved across the proposed items among 24 experts worldwide. Most of the items assessed and that reached consensus corresponded to anatomical structures, and unsurprisingly there was a significant overlap with those included in the ESPR foetal MRI reporting template [11]. In addition, items specific to postmortem imaging were incorporated, including expected postmortem changes and their extent according to the degree of autolysis and maceration [17].

Disagreement (failure to reach the 75% consensus threshold) was observed for several head-related items, such as retrocerebellar CSF spaces and the pinnae, which are known to be affected by postmortem changes (e.g. collapse or deformation) and are therefore perceived to be less reliably assessed [18]. The pinnae can also be evaluated on external examination, with limited added value from MRI. Similarly, consensus was not reached regarding assessment of the number of rays or digits of the upper and lower extremities, as these regions may not be fully covered by the imaging field of view and are often difficult to evaluate on MRI, as is also the case in foetal MRI. Moreover, in the postmortem setting, morphological abnormalities of the upper and lower extremities can be assessed by external examination, and bony abnormalities, including those of the hands and feet, are reliably evaluated using conventional radiographic techniques, which are often performed in this context [19]. It was surprising that our expert panelists disagreed on including ocular spacing in the reporting template, as the interocular distance is a well-established parameter for assessing hypo- or hypertelorism in foetuses [20]. However, this can also be assessed by external examination of the fetus. The rectum and its position relative to the bladder neck were not retained, despite the fact that foetal anorectal anomalies are typically inferred by confirming the presence of meconium at least 10 mm below the bladder neck [21]. It is possible that respondents may have considered this assessment to be part of the evaluation of the "large bowel" and therefore not requiring a separate reporting item documenting the distance between the distal rectum and the bladder neck. Alternatively, they may have considered perineal assessment, including anus position and morphology, to fall within the scope of external examination when excluding anorectal malformations postnatally. Finally, experts did not agree on the inclusion of a standardised normal conclusion statement

Table 1 Results of modified Delphi study

	Percentage of agreement	Agreement reached?
Postmortem changes		
Expected postmortem changes observed	100%	Yes
General extent (mild/moderate/severe)	75%	Yes
Neurological structures		
Supratentorial		
Extraaxial spaces	81.8%	Yes
Symmetry of cerebral hemispheres	100%	Yes
Sulcation	95.5%	Yes
Lateral and third ventricles	100%	Yes
Parenchyma	100%	Yes
Midline structures	100%	Yes
Infratentorial		
Retrocerebellar cerebrospinal fluid spaces	72.2%	No
Fourth ventricle	81.8%	Yes
Brainstem	90.9%	Yes
Vermis	100%	Yes
Cerebellar hemispheres	100%	Yes
Cranio-cervical junction	81.8%	Yes
Face		
Globes	86.4%	Yes
Ocular spacing	68.2%	No
Palate	81.8%	Yes
Mandible	77.3%	Yes
Ears		
Pinnae	59%	No
External auditory canals	77.3%	Yes
Inner ears	77.3%	Yes
Spine and spinal cord		
Vertebral height and alignment	95.5%	Yes
Spinal cord	100%	Yes
Conus medullaris level	100%	Yes
Absence of spine associated subcutaneous mass	81.8%	Yes
Cervicothoracic structures		
Neck/chest		
Thyroid	79.2%	Yes
Thymus	87.5%	Yes
Trachea and main bronchi	100%	Yes
Lung parenchyma	100%	Yes
Diaphragm	83.3%	Yes
Heart		
Atria	91.7%	Yes
Ventricles	95.8%	Yes
Septum	83.3%	Yes
Right ventricular outflow tract	91.7%	Yes
Left ventricular outflow tract	91.7%	Yes
Systemic and pulmonary venous return	75%	Yes
Abdominal structures		
Abdominal wall	87.5%	Yes
Liver	100%	Yes

Table 1 (continued)

	Percentage of agreement	Agreement reached?
Gallbladder and biliary tree	100%	Yes
Spleen	91.7%	Yes
Urogenital tract		
Adrenals	95.8%	Yes
Kidneys and ureters	100%	Yes
Urinary bladder	100%	Yes
Internal genitalia (presence of uterus)	79.2%	Yes
Gastro-intestinal tract		
Stomach	91.7%	Yes
Small bowel	87.5%	Yes
Large bowel	91.7%	Yes
Rectum (position relative to bladder neck)	70.8%	No
Extremities		
Upper extremities		
Normal anatomy	91.7%	Yes
Number of rays/digits	58.3%	No
Lower extremities		
Normal anatomy	91.7%	Yes
Number of rays/digits	58.3%	No
Conclusion		
Expected postmortem appearance (if no significant maceration) or expected postmortem appearances allowing for degree of maceration/ within limits of the examination (if macerated but still diagnostic imaging)	83.3%	Yes
No morphological abnormalities identified	66.7%	No

Percentage agreement among the expert panel in the modified Delphi survey (n=24). Agreement ("yes") was defined as ≥75% of responses indicating agreement

(i.e. "no morphological abnormalities identified"). Most of the remaining anatomical items included in the reporting template achieved a high level of agreement (>80%), with the exception of visualisation of the mandible, external auditory canals, and inner ears (77.3%); systemic and pulmonary venous return (75%); and the thyroid (79.2%). These structures are small and can be challenging to visualise, particularly in fetuses of low gestational age, and might therefore be less consistently assessed in routine practice, being more commonly evaluated in specific clinical contexts.

A consensus threshold of 75% agreement was applied to define inclusion of items in the standardised PMMRI reporting template. This threshold is widely used in Delphi methodology and represents a pragmatic balance between achieving strong expert agreement and accommodating variability in clinical practice among an international panel of 24 participants [16]. In the context of paediatric postmortem MRI, this approach was considered particularly appropriate, as the distinction between normal postmortem changes and pathology can be challenging, and imaging appearances may vary with gestational age, postmortem interval and local protocols. Allowing for a degree of variability while still requiring substantial agreement supports the development of a robust and clinically applicable reporting framework.

While several guidelines and recommendations have been established in the field of perinatal PMMRI [22], none specifically addresses standardised and structured reporting. An example of a standardised report for perinatal and paediatric postmortem CT has been provided by the ESPR TF [23], and some key anatomical structures to be analysed in foetal PM MRI have been provided in a recently published reference book on foetal and paediatric postmortem imaging [24]. Structured reporting has been shown to improve the quality of radiological reports, reduce variability among readers, and enhance communication with referring clinicians, ultimately facilitating more efficient integration of imaging findings into the clinical care pathway [4, 25]. While some specialised centres may already use locally developed templates, formal practice guidelines have been lacking. This gap is particularly relevant in a growing field where centres seeking to implement PMMRI require reliable frameworks on which to base their practice. This template bridges the current gap by

INDICATION / CLINICAL DETAILS / HISTORY

- Neonatal or fetal demise (IUD or TOP):
- Singleton or multiple pregnancy:
- Gender:
- Gestational age:
- Date and time of fetal demise or neonatal death:
- Date and time of delivery:
- Obstetrical and/or neonatal history:
- Prenatal/neonatal imaging findings:
- Amniocentesis findings (including results of genetic testing):
- Physical external examination findings:
- Provisional clinical diagnosis and specific query to be addressed by PMI:
- Is a conventional autopsy planned after PMI?

TECHNIQUE

The fetus/infant was imaged at 1.5/3T, following departmental/national/international/ESPR protocol.
Whole body 3D T2 and T1-weighted sequences with multiplanar reconstructions.
Axial T2*, DWI and T2 TSE sequences of the brain.

FINDINGS

Expected postmortem changes observed: overlapping of skull bones, pleural and pericardial effusion, ascites, bowel distension, subcutaneous edema.
General extent: mild / moderate / severe.

Cerebral structures – visualized and normal

Supratentorial: Extraaxial spaces, symmetry of cerebral hemispheres, sulcation, lateral and third ventricles, parenchyma. Midline structures (corpus callosum, cavum septum pellucidum, pituitary gland).
Infratentorial: Fourth ventricle, brainstem, vermis, cerebellar hemispheres, cranio-cervical junction.
Face: Globes, palate, mandible.
Ears: External auditory canals, inner ears.
Spine and spinal cord: Vertebral height and alignment. Spinal cord and conus medullaris level. Absence of spine associated subcutaneous mass.

Cervicothoracic structures – visualized and normal

Neck/chest: Thyroid, thymus, trachea and main bronchi, lung parenchyma, diaphragm.
Heart: Atria, ventricles, septum, right and left ventricular outflow tract, aorta, systemic and pulmonary venous return.

Abdominal structures – visualized and normal

Abdominal wall, liver, gallbladder and biliary tree, spleen.
Urogenital tract: adrenal glands, kidneys and ureters, urinary bladder, internal genitalia.
Gastro-intestinal tract: Stomach, small bowel, large bowel (including signal characteristics of luminal content).

Extremities – visualized and normal

Upper extremities: Normal anatomy.
Lower extremities: Normal anatomy.

CONCLUSION

Expected postmortem appearance (if no significant maceration) / normal postmortem appearances allowing for degree of maceration / within limits of the examination (if macerated but still diagnostic imaging).

Fig. 1 Standardised and structured clinical foetal/neonatal postmortem magnetic resonance imaging reporting template developed from expert consensus on findings and conclusions and existing published recommendations on indications and imaging technique [14, 15]. The template lists predefined report items with default text for normal findings and provides dedicated fields for systematic documentation of abnormalities when present. *3-D* three-dimensional, *DWI* diffusion-weighted imaging, *ESPR* European Society of Paediatric Radiology, *IUD* intrauterine demise, *MRI* magnetic resonance imaging, *PMI* postmortem imaging, *T* tesla, *TOP* termination of pregnancy, *SWI* susceptibility-weighted imaging, *TSE* turbo spin echo

providing a comprehensive and consensus-based reporting template for foetal and neonatal PMMRI, which may be particularly useful for radiologists with limited prior experience in postmortem imaging. The proposed template provides a predefined list of reportable items for a normal examination, including default statements (e.g. "normal anatomy"), while simultaneously offering a structured framework for documenting and localising abnormalities when present.

There are several limitations to our work. Firstly, the Delphi method of investigation is subjective and based on expert opinion. However, where both expertise and medical evidence are not widely available, combining shared knowledge and experiences provides a helpful framework for other professionals. The anonymous design of the survey may also have encouraged participants to express their views more freely. In addition, although our expert panel was international and diverse, including paediatric postmortem imaging specialists from Europe, Oceania, Asia, and North and South America, the number of participants was limited. Perspectives from underrepresented regions and other professional groups are therefore welcome in future initiatives. Pathologists were not included in this study; while this represents a limitation, the proposed reporting template may nevertheless support and inform pathological examination by highlighting relevant imaging findings and anatomical regions of interest, thereby helping to guide and complement subsequent conventional autopsy.

Taking this work forward, we encourage readers to implement this reporting template in their own clinical practice (Fig. 1), and adapt it as required, to meet local institutional or regulatory requirements. National and international paediatric radiology societies may support translation of the template into different languages. Its integration into clinical workflows has the potential to support consistent reporting practices, improve communication, and identify areas for future development and research. In addition, the structured and digital nature of this template facilitates integration into radiology information systems, supports interoperability across platforms, and provides a foundation for future applications involving artificial intelligence and large language models.

Conclusion

A standardised and structured reporting template for foetal and neonatal PMMRI was developed through expert consensus to promote complete, clear and consistent reporting and to facilitate communication. These recommendations aim to promote standardisation and wider adoption of perinatal PMMRI in clinical practice.

Supplementary information The online version contains supplementary material available at https://doi.org/10.1007/s00247-026-06634-x.

Acknowledgements Aurélie D'Hondt acknowledges the support of the Belgian Kids Fund through a personal PhD grant.

Author contribution All authors contributed to the study conception and design. Material preparation, data collection and analysis were performed by A.D., E.M, S.G., M.C. and O.A. The first draft of the manuscript was written by A.D. All authors read, commented and approved the final manuscript.

Data availability All data supporting the findings of this study are available within the paper and its Supplementary Information.

Declarations

Conflicts of interest The authors declare no competing interests.

References

1. Shelmerdine SC, Arthurs OJ (2023) Postmortem perinatal imaging: what is the evidence? Br J Radiol 96:20211078
2. Gunn AJ, Mangano MD, Choy G, Sahani DV (2015) Rethinking the role of the radiologist: enhancing visibility through both traditional and nontraditional reporting practices. Radiographics 3:416–423
3. Nobel JM, Kok EM, Robben SGF (2020) Redefining the structure of structured reporting in radiology. Insights Imaging 11:10
4. European Society of Radiology (2018) ESR paper on structured reporting in radiology. Insights Imaging 9:1–7
5. European Society of Radiology (2023) ESR paper on structured reporting in radiology-update 2023. Insights Imaging 14:199
6. Tersteeg JJC, Gobardhan PD, Crolla RMPH et al (2018) Improving the quality of MRI reports of preoperative patients with rectal cancer: effect of national guidelines and structured reporting. AJR Am J Roentgenol 210:1240–1244
7. Goldberg-Stein S, Chernyak V (2019) Adding value in radiology reporting. J Am Coll Radiol 16:1292–1298
8. Kahn CE, Heilbrun ME, Applegate KE (2013) From guidelines to practice: how reporting templates promote the use of radiology practice guidelines. J Am Coll Radiol 10:268–327
9. Dunnick NR, Langlotz CP (2008) The radiology report of the future: a summary of the 2007 intersociety conference. J Am Coll Radiol 5:626–629
10. Kahn J, Langlotz CP, Burnside ES et al (2009) Toward best practices in radiology reporting. Radiology 252:852–856
11. Sofia C, Aertsen M, Garel C, Cassart M (2024) Standardised and structured reporting in foetal magnetic resonance imaging: recommendations from the Fetal Task Force of the European Society of Paediatric Radiology. Pediatr Radiol 54:1566–1578
12. Van der Mee FAM, Ottenheijm RPG, Gentry EGS et al (2025) The impact of different radiology report formats on patient information processing: a systematic review. Eur Radiol 35:2644–2657. https://doi.org/10.1007/s00330-024-11165-w
13. Busch F, Hoffmann L, Dos Santos DP et al (2025) Large language models for structured reporting in radiology: past, present, and future. Eur Radiol 35:2589–2602. https://doi.org/10.1007/s00330-024-11107-6
14. D'Hondt A, Shelmerdine S, Arthurs O, ESPR Postmortem Task Force collaborators (2024) Fetal and neonatal postmortem imaging referral template: recommendations from the European Society of Paediatric Radiology postmortem Task Force. Pediatr Radiol 54:1713–1719

15. D'Hondt A, Shelmerdine S, Aertsen M et al (2025) Fetal and neonatal postmortem magnetic resonance imaging clinical protocol: recommendations from the European Society of Paediatric Radiology postmortem task force. Pediatr Radiol 55:2047–2053
16. Diamond I, Grant R, Feldman B et al (2014) Defining consensus: a systematic review recommends methodologic criteria for reporting of Delphi studies. J Clin Epidemiol 67:401–409
17. Hustings N, Thonissen Y, Cockmartin L et al (2023) Fetal brain maceration score on postmortem magnetic resonance imaging vs. conventional autopsy. Pediatr Radiol 53:929–941
18. Arthurs O, Barber J, Taylor A, Sebire N (2015) Normal perinatal and paediatric postmortem magnetic resonance imaging appearances. Pediatr Radiol 45:527–535
19. Arthurs O, Calder A, Kiho L, Taylor A, Sebire N (2014) Routine perinatal and paediatric postmortem radiography: detection rates and implications for practice. Pediatr Radiol 44:252–7
20. Paquette L, Jackson H, Tavaré C et al (2009) In utero eye development documented by foetal MR imaging. AJNR Am J Neuroradiol 30:1787–1791
21. Hyde G, Fry A, Raghavan A, Whitby E (2020) Biometric analysis of the foetal meconium pattern using T1 weighted 2D gradient echo MRI. BJR Open 2:20200032
22. Whitby E, Offiah AC, Shelmerdine SC et al (2021) Current state of perinatal postmortem magnetic resonance imaging: European Society of Paediatric Radiology questionnaire-based survey and recommendations. Pediatr Radiol 51:792–799
23. Shelmerdine S, Arthurs O (2024) How to report perinatal and paediatric postmortem CT. Insights Imaging 15:129
24. Post mortem Imaging of the fetus & Child. Springer (2025) Ed: Arthurs OJ . ISBN 978–3–031–69694–7. https://doi.org/10.1007/978-3-031-69694-7
25. Schwartz LH, Panicek DM, Berk AR et al (2011) Improving communication of diagnostic radiology findings through structured reporting. Radiology 260:174–181

Publisher's Note Springer Nature remains neutral with regard to jurisdictional claims in published maps and institutional affiliations.

Springer Nature or its licensor (e.g. a society or other partner) holds exclusive rights to this article under a publishing agreement with the author(s) or other rightsholder(s); author self-archiving of the accepted manuscript version of this article is solely governed by the terms of such publishing agreement and applicable law.

Authors and Affiliations

Aurélie D'Hondt[1,2] · Marie Cassart[3] · Elka Miller[1,4] · Willemijn M. Klein[5] · Susan Shelmerdine[6,7] · Michael Aertsen[8,9] · Eléonore Blondiaux[10] · Marianne Alison[11] · Ajay Taranath[12] · Christian Abel[13] · Monica Rebollo Polo[14] · Marta Gomez-Chiari[14] · Teresa Victoria[15] · Padma Rao[16] · David Perry[17] · Lizbet Perez-Marrero[18] · Sudha A. Anupindi[19] · Manisha Jana[20] · Andrea Levai[21] · Giana Izzo[22] · Megan B. Marine[23] · Rick R. van Rijn[24] · Stacy Goergen[25,26] · Owen J. Arthurs[6,7]

✉ Aurélie D'Hondt
aurelie.dhondt@sickkids.ca

✉ Owen J. Arthurs
owen.arthurs@gosh.nhs.uk

Marie Cassart
mcassart@his-izz.be

Elka Miller
elka.miller@sickkids.ca

Willemijn M. Klein
willemijn.klein@radboudumc.nl

Susan Shelmerdine
susan.shelmerdine@gosh.nhs.uk

Michael Aertsen
michael.aertsen@uzleuven.be

Eléonore Blondiaux
eleonore.blondiaux@aphp.fr

Marianne Alison
marianne.alison@aphp.fr

Ajay Taranath
ajay.taranath@sa.gov.au

Christian Abel
christian.abel@health.nsw.gov.au

Monica Rebollo Polo
monica.rebollo@sjd.es

Marta Gomez-Chiari
marta.gomez@sjd.es

Teresa Victoria
tvictoria1@mgh.harvard.edu

Padma Rao
padma.rao@rch.org.au

David Perry
dperry@adhb.govt.nz

Lizbet Perez-Marrero
lizbet.perez@gmail.com

Sudha A. Anupindi
anupindi@chop.edu

Manisha Jana
manishajana@gmail.com

Andrea Levai
andrealevai@hotmail.com

Giana Izzo
izzo.giana@asst-fbf-sacco.it

Megan B. Marine
mbshelto@iu.edu

Rick R. van Rijn
r.r.vanrijn@amsterdamumc.nl

Stacy Goergen
stacy.goergen@monashhealth.org

[1] Department of Diagnostic and Interventional Radiology, Hospital for Sick Children, 555 University Avenue, Toronto, ON M5G1X8, Canada

[2] Université Libre de Bruxelles, Brussels, Belgium

[3] Department of Radiology, Hôpitaux Iris Sud, Brussels, Belgium

[4] Department of Medical Imaging, University of Toronto, Toronto, Canada

[5] Department of Medical Imaging, Radboud University Nijmegen Medical Centre, Nijmegen, Netherlands

[6] Department of Clinical Radiology, Great Ormond Street Hospital, London, United Kingdom

[7] Great Ormond Street Hospital Biomedical Research Centre, London, United Kingdom

[8] Department of Radiology, Universitair Ziekenhuis Leuven, Leuven, Belgium

[9] Translational MRI, Department of Imaging and Pathology, KU Leuven, Leuven, Belgium

[10] Department of Pediatric Radiology, Hôpital Armand-Trousseau, Paris, France

[11] Department of Pediatric and Fetal Imaging, Hôpital Robert-Debré, Paris, France

[12] Department of Medical Imaging, Women's and Children's Hospital, Adelaide, Australia

[13] Department of Medical Imaging, John Hunter Hospital, Newcastle, Australia

[14] Department of Medical Imaging, Hospital Sant Joan de Déu Barcelona, Barcelona, Spain

[15] Department of Medical Imaging, Massachusetts General Hospital, Boston, United States

[16] Department of Medical Imaging, Royal Children's Hospital, Melbourne, Australia

[17] Department of Medical Imaging, Auckland City Hospital, Auckland, New Zealand

[18] Diagnostic Imaging Department, Clínica Alemana, Santiago, Chile

[19] Department of Radiology, Children's Hospital of Philadelphia, Philadelphia, United States

[20] Department of Radiodiagnostic and Interventional Radiology, All India Institute of Medical Sciences, New Delhi, India

[21] Department of Radiology, Our Lady's Hospital, Navan, Ireland

[22] Departement of Radiology and Neuroradiology, Ospedale dei Bambini Vittore Buzzi, Milan, Italy

[23] Department of Medical Imaging, Riley Hospital for Children, Indianapolis, United States

[24] Department of Radiology and Nuclear Medicine, Amsterdam University Medical Centers, Amsterdam, Netherlands

[25] Monash Imaging, Monash Health, Melbourne, Australia

[26] Department of Radiology and Radiological Sciences, Monash University, Melbourne, Australia